

**INTERCONDYLAR FRACTURE OF HUMERUS, MULTIPLE ULNAR FRACTURE, AND BRIDGE OF SHELL FRACTURE
IN A TURTLE - A CASE REPORT**

Piyabongkarn Damrongdej

Linthong Veterinary Clinic, Bangkok, Thailand

ABSTRACT

A turtle was severe front limb bone fracture (humerus, ulnar), and bridge of shell fracture from grass cutter that was repaired by screw, intramedullary pin, wire, and 21G needle for stabilization of humerus, and ulnar fracture. The shell was fixed by epoxy resin adhesive. This report showed successful method in easy way, and economic cost in fixing tiny limbs bone complication fracture.

Keywords: turtle, humerus, ulnar, shell, fracture

No: of Figures: 05

No: of References: 03



INTRODUCTION

Front limb injury is not common case in the turtle. The common treatment in turtle limb injury is external elastic bandage, but the external bandage is not suitable treatment for the turtle because of the residence of turtle is important for the turtle life. The moisture of external bandage can lead to complication problem. Internal fixation by steinman pin and screw fixation is the good method for repairing limb bone fracture.

Case history and clinical observation

A turtle (Malayan Snail-eating turtle) weighting around 1.5 kg was brought to Linthong Vet. Clinic. A turtle showed laceration of right front limb, and right bridge of shell fracture (Fig-1,2) The massive blood was lost from the wound. Radiography showed bridge of shell fracture, intercondylar fracture of humerus, and multiple ulnar fracture (Fig-3)

Anesthetic method

A turtle was anesthetized by 4% isoflurane mask induction [1,3]. The stage of anesthesia was carefully observed. The mask of isoflurane was used at the concentration 3-4% during surgical procedure.

Surgical procedure

The wound was cleaned by iodine solution. The intercondylar fracture was retracted to correct position by 2.0 mm screw fixation and screwed condyle was retracted to the

distal humerus by 1.0 mm steinman pin. Multiple ulnar fractures were managed by 21G hypodermic needle instead of steinman pin because the ulnar bone was tiny. The diameter of bone was smaller than the pin. Due to sharp and force of grass cutter destroyed the carpal and elbow joint capsule, also normograde insertion of the pin was used to fix of ulnar fracture. 21G needle was attached three ml syringe and 21G needle was inserted from the distal ulnar to proximal ulnar by passing the fracture line. Full cerclage wire was used to that ancillary instrument for the fixed other ulnar bone fragments. The lacerated limb muscles were sutured by 3/0 chromic catgut, and the skin was sutured by nylon 2/0. Elastic bandage was applied to the limb 10 days (Fig-4,5)

Bridge of shell fracture fixation

The bridge fracture was cleaned with iodine solution and was fixed by three layers of fiberglass and epoxy resin adhesive [2].

Post operation

Enrofloxacin was injected to the muscle 5 days continuously. After 8 days, the skin suture was removed. The turtle could swim in the water. She was released to the garden after 10 days of operation and 2 months later, the owner sews the turtle could walk, swim, and lay eggs in the garden.

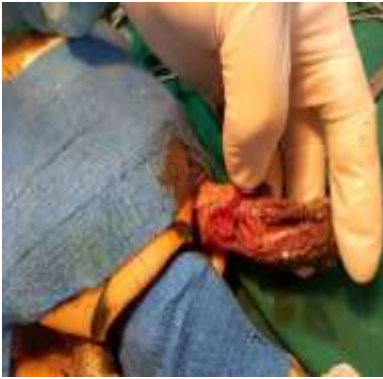


Figure1 Front limb bone fracture and muscle laceration

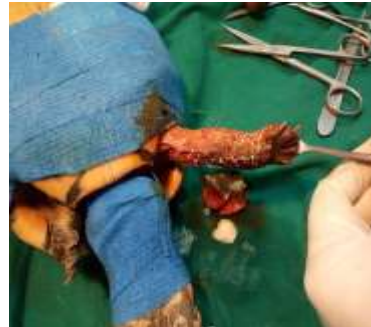

Figure5 Skin suture after operation

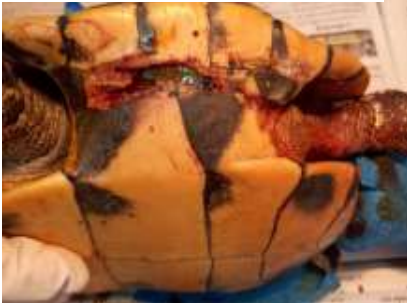

Figure 2 fracture of bridge of shell



Figure 3 Radiograph showed intercondylar fracture of humerus and multiple ulnar fracture

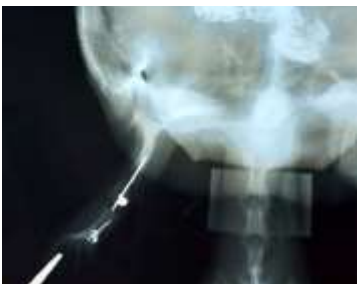

Figure4 Radiograph showed pin, screw, and wire for repairing fracture



Discussion

The internal fixation method for correction of limbs bone fracture in the turtle was reported in a few literatures. The internal fixation is good method for the treatment of limb bone fracture. Pin and wire are appropriate for especially tiny turtle that cannot use bone plate. The external skeleton fixation, and external bandage is not appropriate for water turtle. Due to these procedures use long time for allowing bone healing, and so many complication problems with water turtle. In this case, the suture material was removed and the turtle was released to the residence after 8 days of operation. This turtle has been bridging fracture from the accident. The fiber glass and epoxy resin were used for repairing bridge fracture because returning to the habitat was short time and the bridge wound was not much contaminated by organisms. In this

operation, inhalation anesthesia gas(isoflurane) was selected because its safe more than injectable anesthesia [3]. Two months after surgery, the turtle can walk and run showed that the successful treatment by internal fixation method.

References

- [1] **Nisha J, Jhale SK.** Carapace fracture in a turtle-A case report. *Veterinary World* 2010; 3(7):337-338.
- [2] **Kiyakazu N, Hiroyuki O, Noriko O, Miki S.** Surgical repair of a depressed fracture in a green sea turtle, *Chelonian Mydas.J. Vet.Med. Sci* 2000; 62(1):103-104.
- [3] **Stephen, J.D.** Anesthesia of zoological species. In: Clarke K. W, Trim C.M, and Hall.L. W(ed) *Veterinary anesthesia.* Saunder.Elsevie, pp 535-570,2014.