

WOUND HEALING ACTIVITY OF ETHANOLIC EXTRACT OF ALPINIA GALANGAL LEAVES

Deepa S^{1*}, G.Prabakaran²

¹Research Development centre, Bharathiyar University, Coimbatore,641046, Tamilnadu.

²Department of Botany, Govt Arts College, Dharmapuri, 636701.Tamilnadu.

Email:deepa27081980@yahoo.com

(Received on date:30th June 2012

Date of Acceptance:11th July 2012)

ABSTRACT

Present work was done to explore the wound healing activity of ethanolic extract of *Alpinia galangal* leaves in albino wistar rats. The extract was tested for wound healing activity by excision wound model. 10 g of petroleum jelly and 0.5 g extract was taken to produce 5 % low dose extract. The 10% High dose extract was prepared by stirring 10g of Petroleum jelly with 1.0g of ethanolic extract of *Alpinia galangal*. This 5% and 10% ointment was used for topical application. The extract showed significant response in both the wound types tested when compared with the control group. On the basis of the results it can be said that the extract of *Alpinia galangal* possess wound healing activity.

Keywords: Wound healing, excision, incision, *Alpinia galangal* leaves

Number of Tables : 1

Number of Figures: 4

Number of References:23

INTRODUCTION

Wounds are the visible results of cell death or damage, which can be classified on the basis of site, size, depth and causation like surgery, accident or circulatory failure (Charde et al,2010).

The objective in wound management is to heal the wound in the shortest time possible, with minimal pain, discomfort, and scarring to the patient. In addition to this a flexible and fine scar with high tensile strength is also desired. Hence understanding the healing process is critical to successful management of wound. Wound healing is the process of repair that follows injury to the skin and other soft tissues. This process consists of integrated cellular and biochemical events leading to the re-establishment of structures and functional integrity and regaining strength of the injured tissue (Gupta and Jain, 2010).

A number of drugs ranging from simple non-expensive analgesics to complex and expensive chemotherapeutic agents administered in the management of wound affect healing either positively or negatively (Prasad and Rao, 1995). Aspirin, indomethacin, cytotoxic agents and immunosuppressants have been proved experimentally to affect healing negatively (Lee, 1968, Rao et al, 1991 Raju and Kulkarni, 1986, Holla et al, 1988). Medicinal herbs are an indispensable part of traditional medicine and these have been the basis of treatment and cure for various diseases and physiological conditions in traditional methods practiced such as Ayurveda, Unani and Siddha. India has a rich flora that is widely distributed throughout the country.

One of the Indian medicinal plant

Alpinagalanga belonging to family Zingiberaceae commonly called 'galanga' These tropical plants are tender perennials from India, China and the East Indies and they have thick fragrant rootstocks, resembling the scent of ginger, from which the new shoots sprout in the spring. They can grow up to 10 feet high with a 3-foot spread. Their leaves are lance-shaped with fringed borders and they are produced on reedy stems. The tubular flowers are produced in pendulous clusters. The herb is used in homeopathy as a stimulant. It is because the herb can tone up the tissues of the body. It is helpful in facilitating the process of digestion and prevents eating disorders and flatulence.

Although many indigenous tribes around the world have long been suspected that this ubiquitous, annual, herbaceous plant might have medicinal wound healing properties, it has not really got the attention of orthodox medical practitioners as a potential source of a healing agent which may prove to be useful in the treatment of wounds. Therefore the present study was planned to explore the wound healing activity of Alpinia galangal leaves.

MATERIALS AND METHODS

The work was conducted in the manian institute of science and technology plant material and preparation of herbal extract Alpinia galangal leaves were purchased from GKVK, Agricultural University, Bangalore and authenticated by its morphological characteristics (Evans, 2002). Thoroughly washed leaves of A.galanga were dried in shade for five days and then powdered with the help of Warring blender. 25 g of shade-dried powder was filled in the thimble and

extracted successively with five solvents in Soxhlet extractor for 48h. The solvent extracts were concentrated under reduced pressure and preserved at 5°C in airtight bottle until further use.

For the preparation of various extracts from the *Alpinia galanga* were shade dried at room temperature and powdered by mixer. Petroleum ether, Acetone, chloroform, Ethanol and methanol extract were obtained by successive extraction method by Soxhlet apparatus and aqueous extract by maceration method. All the extracts were concentrated under reduced pressure by rotary vacuum evaporator (Jain *et al.*, 2007).

Chemicals

White Petroleum Jelly – (Central Drug house (P) Ltd, New Delhi).

In vivo studies

Experimental animals

Male albino Wistar rats (150-200 g) used in the present study were procured from the small animals breeding station, Mannuthy, Kerala, India. They were housed in polypropylene cages (38 x 23 x 10cm) with not more than six animals per cage and maintained under standard environmental conditions (14h dark /10h light cycles; temp 25±2°C; 35-60% humidity, air ventilation) and were fed with standard pellet diet (M/s. Hindustan Lever Ltd., Mumbai, India) and fresh water *ad libitum*. The animals were acclimatized to the environment for two weeks prior to experiment use. Animals were fasted over night before the experimental schedule, but have free access for water *ad libitum*.

Wound healing activity Preparation of

Ointment:

To 10g of Petroleum jelly 0.5g of ethanolic extract of *Alpinia galangawas* added and stirred to produce the 5% Low dose extract. The 10% High dose extract was prepared by stirring 10g of Petroleum jelly with 1.0g of ethanolic extract of *Alpinia galangal*. This 5% and 10% ointment was used for topical application (Mohammed Moideen *et al.*, 2011).

Excision Wound model

The rats were divided into four groups of six animals each (n=6). Group I served as induced and Group II as standard which was topically applied with Lyramycin for 21 days after the wound excision. Groups III and IV were topically applied with 5% and 10% (w/w) ointments prepared using the ethanolic extract and petroleum jelly for 21 days. Wounds were created at the back of each animal of Groups I – IV. An area of about 1.0 sq cm is marked out. The marked area is excised with sharp knife and scissors under ether anesthesia (Sainuddin and Haneefa, 2010). The length and breadth of the wounds were measured for 21 days using a verniercaliper. Wound area was measured by tracing the wound on a millimeter scale graph paper. The percentage of wound contraction was calculated of original wound size (500 mm²) for each animal on predetermined days i.e., 3, 6, 9, 12, 15, and 18th days of post wounding for final analysis of results (Kumar and Gupta, 2009). Animals were closely observed for any infection and those which showed signs of infection were separated and excluded from the study and replaced. Sacrificed by cervical dislocation and wound areas from each animal were removed carefully.

Selection of dose and treatment period

Alpinia galangal 10% ointment was used for topical application in excision wound models. The treatment period was 12 days for excision wound models. The day of infliction of wound was considered as day '0'.

RESULTS

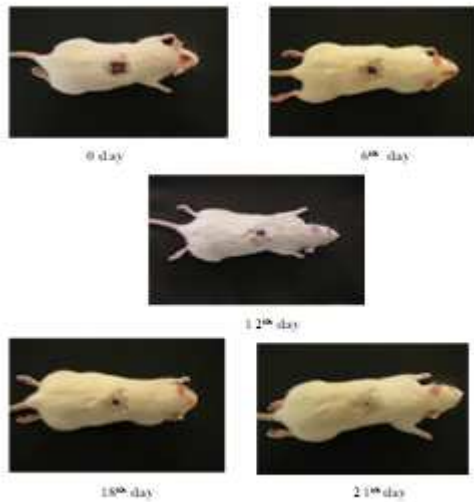

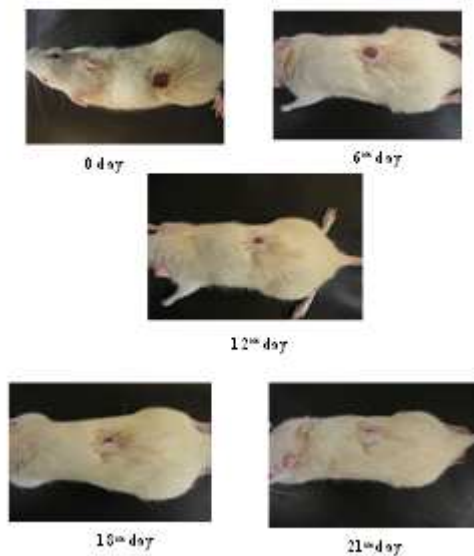
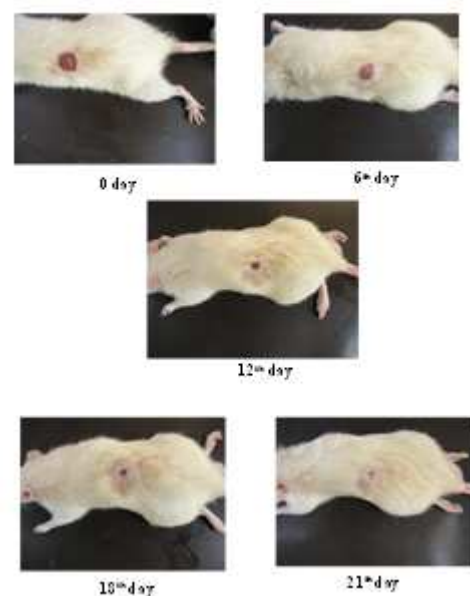
The ethanolic extract of Alpinia galangal leaves (10% w/w) ointment of high dose had produced significant increase in wound contraction (83.1, 94.61 and 99 %)

after 12th day, 15th and 18th day of treatment as compared with Induced (61.57, 82.99, 99.92) (Table 1) (figure 1-4). Similarly a significant increase in wound contraction was seen on 15th day was observed more, as compared with (Table 1) (figure 1-4). The wound contraction and strength of experimental ointment under test were in close proximity with standard antibiotic Lyramycin.

Table 1: Wound healing activity of ethanolic extract of Alpinia galangal

Day No.	Induced		Standard		Low Dose		High Dose	
	Length	Breadth	Length	Breadth	Length	Breadth	Length	Breadth
0 th day	10.52 ± 0.15	10.50 ± 0.15	10.44 ± 0.20	10.44 ± 0.20	11.80 ± 0.62	10.91 ± 0.72	11.23 ± 0.61	10.74 ± 0.57
3 rd day	10.32 ± 0.12	10.43 ± 0.15	8.16 ± 0.16	8.22 ± 0.10	10.99 ± 0.68	10.49 ± 0.85	10.60 ± 0.18	10.16 ± 0.89
6 th day	9.72 ± 0.04	9.62 ± 0.15	6.06 ± 0.04	6.1 ± 0.04	10.23 ± 0.24	10.39 ± 0.38	9.81 ± 0.43	9.92 ± 0.44
9 th day	8.48 ± 0.16	8.59 ± 0.14	4.24 ± 0.08	4.13 ± 0.07	8.73 ± 0.41	8.91 ± 0.58	7.69 ± 0.97	7.17 ± 0.51
12 th day	6.47 ± 0.22	6.56 ± 0.22	2.14 ± 0.09	2.12 ± 0.07	5.70 ± 0.22	5.58 ± 0.32	4.71 ± 0.12	4.33 ± 0.26
15 th day	4.28 ± 0.10	4.39 ± 0.23	0.86 ± 0.03	0.86 ± 0.06	3.59 ± 0.35	3.37 ± 0.31	2.54 ± 0.13	2.56 ± 0.10
18 th day	2.85 ± 0.12	2.83 ± 0.13	Wound healed	Wound healed	2.30 ± 0.18	2.30 ± 0.18	1.10 ± 0.08	1.10 ± 0.08
21 st day	0.99 ± 0.14	0.99 ± 0.14	Wound healed	Wound healed	1.03 ± 0.07	1.03 ± 0.07	Wound healed	Wound healed

Values are expressed as mean ± SD (n=6).

Fig-1**Induced group****Fig-2****Standard group****Fig-3****Low dose group****Fig-4****High dose group**

Wound healing is the primary response to tissue injury with different phases like contraction, granulation, epithelisation and collagenation which is mainly achieved by connective tissue matrix synthesis (Pieree and Mustoer, 1995, Biswas and Mukherjee, 2003).

In our study, in excision wound model, the

ethanolic extract of *Alpinia* leaf extract (10% w/w) ointment has produced significant increase in wound contraction after 15th, 18th, 21st day of treatment as compared with induced group. This suggests that it would have either enhanced contractile property of myofibroblasts or increased the number of myofibroblasts recruited into the wound

area. The wound breaking strength is determined by the rate of collagen synthesis and more so by the maturation process where there is covalent binding of collagen fibrils through inter and intramolecular cross linking (Shanbhag et al, 2006). In the present study a significant increase in wound contraction on 15th day was observed in test group as compared with induced group.

CONCLUSION

The ethanolic extract of *Alpinia galangal* leaves applied topically, effectively increased (87%) the contraction of open wound, after 15-18 days. The results of the study suggest that the leaf extract has significant wound healing activity in excision wound model and it could possibly be made use of clinically, in healing of open wounds. However, implementation of these results need well designed clinical evaluation.

ACKNOWLEDGEMENT

I am thankful to Dr. Anusuya, research coordinator, Manian institute of Science and Technology, Coimbatore

REFERENCES

Biswas T.K., et al (2006). Plant medicines of Indian origin for wound healing activity: A review. *Int J Lower Extremity Wounds*.; 2(1): 25-39, **2003**.

Charde R.M., et al (2010).. Wound healing activity of ethanolic extract of *Rubiocordifolia* roots. *J Phar Res.*; 3(12): 3061-3063..

Ehrich H.P., et al (1969).. Effect of

cortisone and anabolic steroid on tensile strength of healing wound. *Ann Surg.*; 170: 203-206, **1969**.

Evans, W.C. Psyllium. In *Trease and Evans (Ed.) Pharmacognogy.* (pp. 210). Sounder WB Company Limited (2002).

Falanga V. The chronic wound: Impaired wound healing and solution in the context of wound bed preparation, blood cells *mole. Disease.*; 32(84): 88-94, **2004**.

Fernandez B.F., et al (1999). Randomized mesalamine in maintaining remission in ulcerative colitis. Spanish Group for the Study of Crohn's Disease and Ulcerative Colitis (GETECCU). *Am J Gastroenterol.*; 94: 427-433.

Gabbaiani G., et al (1972).. Granulation tissue as a contractile organ. *J Exp Med.*; 135(4): 719-734..

Gupta N., et al (2010).. Prominent wound healing properties of indigenous medicines. *J Nat Pharm.*; 1(1): 2- 5.

Hannan J.M.A., et al. Aqueous extracts of husks of *Plantago ovata* reduce hyperglycaemia in type 1 and type 2 diabetes by inhibition of intestinal glucose absorption. *Br J Nut.*; 96: 131-137..

Holla R.K., et al (1988). Cyclosporin and wound healing. *Ind J Exp Biol.*; 26: 869- 873.

Isabgol cultivation- A profitable cultivation, accessed on date 20/06/2011 <http://www.agricultureinformation.com/photos/showphoto.php?photo=61>.

Kumar N., et al (2009). Wound-Healing Activity of *Onosmahispidium* (Ratanjot) in

Normal and Diabetic Rats. *J Herbs Spices MedPlants.*; 15(4): 342-351.

Kumar N.,et al (2010) .. Estimation of Wound healing activity of Solanum xanthocarpum Schrad & Wendl. Fru its. *Ind J Nat ProReso.*; 1(4): 470-475.

Lee K.H. Studies on the mechanism of action of salicylates III. Effect of vitamin A on the wound healing retardation action of aspirin. *JPharma Sci.*; 57(7): 1238-1240.

Maiere C.M., et al (2002) .. Role of superoxide dismutase in oxidative damage and neurodegenerative disorders. *Neuroscientist.*; 8(4): 323-334..

Marina G.,et al (2003).. Cytotoxic effect of *Plantago* spp. on cancer cell lines. *Journal of Ethnopharmacology.*; 88: 125-130..

Pieree G.F.,et al (1985).. Pharmacologic enhancement of wound healing. *Annu Rev Med.* 46: 467-481..

Prasad D.,et al. Wound healing profile of ketorolac, metronidazole and tinidazole

administered postsurgically. *Ind J Exp Biol.*; 33: 845-847. **1995.**

Raju S.,et al (1986).. Vitamin A reverses the wound healing suppressant effect of cyclophosphamide. *Ind J Pharmacol.*; 18: 154-157..

Rao C.M.,et al (1991).. A simple method to quantify maturation of wound collagen. *Ind J Exp Biol.*; 29: 156-158.

Rodríguez C.M.E.,et al (2002) . Dietary fiber down-regulates colonic tumor necrosis factor alpha and nitric oxide production in tri nitro benzene sulfonic acid-induced colitic rats. *J Nutr.*; 132(11): 3263-3271..

Rodríguez C.M.E.,et al (2003).. Intestinal anti-inflammatory activity of dietary fiber (*Plantago ovata* seeds) in HLA-B27 transgenic rats. *Clin Nutria.*; 22(5): 463-471..

Shanbhag T.V.,et al (2006). Wound healing activity of alcoholic extract of *Kaempferia galanga* in wistar rats. *Indian J Physiol Pharmacol.*; 50(4): 384-390..