

# SEQUENTIAL USE OF HYDROQUINONE (HQ) BASED (WITHOUT STEROID AND TRETINOIN) FORMULATION FOLLOWED BY NON-HQ BASED FORMULATION IN TREATMENT OF MELASMA IN INDIAN PATIENTS: A PROSPECTIVE NON RANDOMIZED STUDY

Dr Satish Udare., Dr Dhammraj Borade., Dr Varsha Narayanan., & Dr Harsha Mahajan.,

Affiliation: Consultant Dermatologist, Sparkle Skin care, Vashi, Navi-Mumbai, Maharashtra India

Affiliation: Medical Advisor, Department of Medical Scientific Affairs, Wockhardt Limited, Mumbai, Maharashtra, India

Affiliation: Head, Department of Medical Scientific Affairs, Wockhardt Limited, Mumbai, Maharashtra, India

Affiliation: Consultant Dermatologist, Skinovate Skin center, Pimple Saudagar, Pune, Maharashtra India

(Received on Date: 26<sup>th</sup> October 2017

Date of Acceptance: 24<sup>th</sup> November 2017)

## ABSTRACT

Despite the availability of multiple treatments for melasma, the limited efficacy of conventional therapies is a clinical management challenge. A novel sequential regimen based on multi modal bio-innovative combination therapy was designed for the treatment of patients with melasma. To assess the safety and efficacy of a sequential treatment regimen to treat melasma in Indian patients. A non-randomized, single arm sequential phase study was conducted in two phases for a duration of 12 weeks. The intensive phase lasted 4 weeks where patients applied topical treatment with hydroquinone (HQ) based formulation followed by maintenance phase (8 weeks) with non HQ treatment. Mean change in melasma severity index (MSI) score from baseline and melasma specific quality of life (MELASQOL) scores were evaluated using established and validated scales and questionnaires to measure the efficacy of treatment. The adverse events (AE) were noted at the end of both the phases. A significant change in mean MSI score from baseline was observed after 4 weeks ( $-11.67 \pm 9.35$ ,  $p=0.001$ ) and 12 weeks ( $-17.65 \pm 13.00$ ,  $p=0.001$ ) of treatment. Significant improvement ( $-08.56 \pm 6.36$ ,  $p=0.001$ ) in melasma specific QoL was reported after 4 weeks of first regimen usage which further improved and was maintained after 8 weeks of second regimen application ( $-16.38 \pm 12.29$ ,  $p=0.00$ ). The mean global AE score was 1.94 at Week 4 and 0.00 at Week 12. Overall, 70% patients reported good to excellent improvement at the end of the treatment. Treatment of melasma with sequential regimen of Depiwhite is safe, effective and can be recommended for prolonged use.

**Keywords:** Hyperpigmentation; Melasma severity index (MSI), Quality of life (QoL), Sequential regimen, Hydroquinone (HQ), Dermatology

## INTRODUCTION

Hyperpigmentation or melasma is the most common acquired skin disorder characterized with light to dark brown macules and patches mostly found on neck and face. The condition is sometimes localized, as in the case of post-inflammatory hyperpigmentation (PIH), or sometimes more diffuse (1, 2). The etiology is not yet fully understood, but several hypotheses have been suggested (3, 4). In India, due to wide ethnic variations and people existing with different skin types, the dermatologists find it challenging to treat (5, 6). The current treatments available for melasma have limited efficacy, and fail to control melanocyte hyperplasia and melanosomes production rate. Non aggregated melanosomes are found in rich quantity in melasma skin as compared to the normal skin. These are not easily digested in the epidermis and result in induction of a long-term hyperpigmentation. The current therapies have no added effect on peculiar melasma pathology (3, 7, 8). The first gold standard treatment approved by Food and drug administration (FDA) for melasma was Kligman and Willis regime; a triple combination (TC) therapy consisting of hydroquinone (HQ) at a concentration of 5% in combination with steroid (0.1% dexamethasone) and tretinoin (0.05%) regimen. Improvement with this treatment is usually observed at 4 to 6 weeks, with a plateau at 4 months (9). Currently this regimen is not favored due to its serious risks of steroid induced skin atrophy,

hypertrichosis, acneiform eruption and development of topical steroid damage face (TSDF). High concentration of HQ and tretinoin increases skin irritation and sensitivity. This regimen has not been found suitable for Indian patients with fitzpatrick type IV-VI skin.(10, 11) Later, various FDA approved formulations were launched; Pathak's (2% HQ and 0.05-0.1% tretinoin) and Westerhof's formula (4.7% N-acetylcysteine, 2% HQ and 0.1% triamcinolone acetonide) that usually takes 4 to 8 weeks to show significant improvement and maximum results. These combinations are presently considered as the first line therapies in melasma (12, 13). However as per FDA, these combinations should not be used for a longer duration (>4-8 weeks) due to the risk of HQ inherent AEs (ochronosis) (4). Further, once the therapy is discontinued, there is a chance of relapsing hyperpigmentation (14).

Other promising options include; chemical peels, laser and light therapies for patients who are refractory to other modalities but these therapies are usually associated with poor follow up care, have high risk of relapse and other post treatment side effects especially in darker skin types which are more prone to PIH (3, 15, 16). To overcome the various demerits of current treatments, there is a need to develop a bio-innovative multi modal approach to achieve fast superficial and deep sustained depigmentation therapy. We studied a new sequential regimen using HQ based steroid and tretinoin free

regimen in intensive phase and non HQ based formulation in the maintenance phase. Both regimens used in the sequential phases are already available in market under tradenames; Depiwhite cream and Depiwhite advanced (manufactured by Wockhardt Ltd. India), respectively. Depiwhite cream is composed of HQ (2%), kojic acid (2%), vitamin C (0.5%), antipollon (1%) and vitis vinifera oil.

Depiwhite Advanced comprises of kojic acid (2%), vitamin C (2%), plant extract (Arbutin, Luteolin, Parsley; 2%), antipollon(1.5%), phosphatase activators [ $Mg^{2+}$ ,  $Mn^{2+}$ ;1%], vitamin PP (Niacinamide;1%) and esterified lactic acid (8%).

This sequential regimen is designed so as to offer a prolonged remission and at the same time, is safe even on repeated use. The present study was conducted to evaluate the safety and efficacy of sequential regimen of Depiwhite in patients with melasma.

## Methodology

### Study Type and Duration:

It was a non-randomized, single center, single arm, interventional, sequential phase study. The study was conducted at Skinovate skin center Pune, India. The study protocol (2016/10/2002) was approved by Skinovate Laser and Cosmetic Surgery Center LLP, Pune, India. The study conformed to the guidelines of the Declaration of Helsinki. All the participants received Depiwhite sequential topical regimen treatment for a period of 12 weeks. The study was divided into two

phases; intensive phase (4 weeks) wherein Depiwhite cream was prescribed once daily at bed time followed by the maintenance phase (8 weeks) in which Depiwhite advanced was prescribed for twice(morning and at bed time) daily use. All the patients were instructed to avoid sun or heat exposure and rubbing or scratching of the treated areas. Also, they were instructed to use a daily broad spectrum sunscreen and to avoid any other skin treatments while undergoing study.

### Participants' enrollment

A total of 50 (76% women) patients in the age group of 23-55( $37.24 \pm 9.55$ ) years were enrolled. All the patients were informed about the study procedures, risks, benefits, potential complications, and the consequential AEs. The participants who opted to take part were included in the study after signing an informed consent form. All the patients were examined for their demography characteristics including; age, gender, skin type and pattern of melasma.

**Measurement of Outcomes:** The primary outcome variable of the study was Mean change in MSI score from baseline. The secondary outcome variables included safety of the sequential therapy and effect on melasma specific QoL

### Efficacy Outcomes:

**Progress Assessment by Melasma Severity Index (MSI) Score:** Mean change in MSI score was evaluated from baseline (Week 0, at the start of treatment), Week 4 (at the end of Depiwhite cream treatment) and

Week 12, (at the end of Depiwhite Advanced cream treatment) using latest MSI scoring scale devised by Majid I. *et al*(17) (**Appendix 1**).

#### **Change in Mean Melasma Quality of Life**

**(QoL) Score:** The QoL scores were assessed using standard 10 item Melasma Specific Quality of Life Scale(MELASQOL) questionnaire devised by Balkrishnan and colleagues in 2003(18). It is a universally accepted and validated tool that uses a Likert scale of 1 to 7 in which 1 signifies “not bothered at all” and 7 signifies “bothered all the time” due to the skin condition. MELASQOL scores range from 7 to 70, a higher score signifying worse QoL (18, 19). The questions were designed on the basis of patients' improvement in skin conditions throughout the treatment. The scores were evaluated from the start of the treatment (Week 0), at Week 4 and at the end of the treatment (Week 12). Wilcoxon sign rank test was applied to calculate the significant difference for mean difference of scores from baseline to Week 4 and from baseline to Week 8.

#### **Safety Outcomes:**

##### **Change in Mean Total Adverse Events (AE)**

**score:** The AEs; dryness (a), erythema ( b) and skin irritation(c) were evaluated on Week 4 and Week 12. Significant changes in mean scores were calculated using Wilcoxon sign rank test and Mann Whitney U test.

##### **Change in Mean Global Adverse Events**

**(AE) score:** The total mean global AE scores (a+b+c) were evaluated at Week 4 and Week 12. Significant changes in mean

scores were calculated using Wilcoxon sign rank test and Mann Whitney U test.

#### **Results**

##### **Efficacy Outcomes: Melasma Severity Index (MSI) Score:**

The study reported baseline mean score of MSI 30.42. A fall of 38.4% (4 weeks) and 58% (12 weeks) was observed in MSI score from baseline. A significant reduction in mean MSI score ( $-11.67 \pm 9.35$ ,  $p=0.001$ ) was observed after 4 weeks and 12 weeks ( $-17.65 \pm 13.00$ ,  $p=0.001$ ) of treatment from baseline (**Figure 1**).

##### **Change in Mean Melasma Quality of Life (QoL) Score:**

The study reported a significant improvement in QoL of patients using sequential regimen. The mean QoL score at baseline was 51.32 that reduced to 16.7% at the end of Week 4. At Week 12, after treatment with Depiwhite advanced, the mean melasma QoL score showed a significant reduction of 32 % from baseline. A significant improvement( $- 08.56 \pm 6.36$ ,  $p=0.001$ ) in melasma specific QoL was seen after 4 weeks of treatment which was further improved and maintained after 8 weeks of treatment. ( $-16.38 \pm 12.29$ ,  $p=0.001$ ) (**Figure 2**)

##### **Safety Outcomes: (Table1)**

##### **Change in Mean Total Adverse Events (AE) score:**

At the end of Week 4, 68.0%, 10% and 64% of the patients had mild to moderate skin dryness, erythema and irritation, respectively. The study reported that the mean total AE score for dryness, erythema, and irritation was 0.84, 0.10 and 1.02,

respectively at Week 4. The patients showed 100% improvement, i.e., mean total AE score was 0 at the end of the study (Week 12), as none of the patient reported an AE. Both the treatments were well tolerated; even initial minor dryness and irritation were further minimized after the use of second formulation in maintenance phase. .

### **Change in Mean Global Adverse Events (AE) score**

The study reported that the mean global AE score was 1.96 at Week 4 and 0.00 at Week 12. The results showed a significant faster response in initial phase and further incremental improvement in second phase..

### **Clinical Evaluation**

As per the investigators' rating scales, good to excellent efficacy of the treatment was observed in 70.0% of the patients (Figure 3)

### **Discussion**

Melasma is a refractory and recurrent skin pigmentation disorder which greatly influences the QoL of the affected individuals impacting their physical appearance as well as emotional state (20-23). Despite numerous advances in understanding the management of melasma, the clinical management is still frustrating as many modalities turned out to be ineffective (4). Various clinical studies conducted in the past using monotherapy and the combination therapies reported beneficial results, but, had limitations of

relapsing and recurrence of the condition (10, 24, 25).

In the present study, the HQ and Non-HQ formulations were used sequentially in patients with melasma. This sequential regimen has proven to be a pro-active treatment approach that has accurate blend of therapeutic active ingredients and natural extracts to provide visible and sustained depigmentation effects with good tolerance. The therapeutic ingredients; kojic acid; potential inhibitor of NF Kappa B activation induces anti-melanogenic effect, vitamin C and plant extracts reduce rate of melanin synthesis and vitamin PP blocks the process of melanin transfer, antipollon, a unique bio-innovative patented substance adsorbs and discharges excess surface melanin, which is useful in inducing a fast and visible whitening effect. Acid phosphatase activators ( $Mg^{2+}$  and  $Mn^{2+}$ ), another bio-innovative component, increase the rate of melanin biodegradation in keratinocytes, these activators block the oxidative pathways and limit tyrosinase activity, thereby reducing melanin synthesis (26). Currently, most of the available therapies fail to target melanin degradation which is also one of the etiopathological mechanism in melasma (10, 27). The formulation used in maintenance phase specifically targets the acid phosphatase enzyme that regulates the melanin biodegradation and other skin repairing mechanisms which play a vital role in melanin synthesis, transfer, degradation, adsorption and exfoliation (26).

The synergistic effect of both the formulations has shown significant improvement in patients. Instant effect on skin depigmentation was reported within the first four weeks of treatment application with HQ based formulation, which was further maintained by non HQ and steroid free combination formulation in follow up study of eight weeks. Skin lightening at all the areas increased gradually over the treatment period and became most significant at the end of study period. The advantage of switching on to alternative treatment after the prolonged use of HQ treatment is that it overcomes the ochronosis and also resolves the poor patient therapy adherence. Hence, its therapeutic effects are more persistent and faster, also it is free from corticosteroids and tretinoin and thus has lesser AEs and can be recommended for prolonged use (2-6 months).

To evaluate the clinical effectiveness of any melasma treatment in terms of severity and extent, dermatologists assess MSI or, MELASQOL value which has correlation with this scale, demonstrating that, for patients, the impact of the disease is typified by criteria other than its clinical severity as assessed by the physician.(12). We have also studied MSI and QOL scores, MSI score was calculated by multiplying the area of involvement with the square of pigmentation score to give the latter variable its due importance in assessing disease severity. Secondly, the assessment was performed separately on the "nose" to consider the non-uniform nature of pigmentation in some cases of melasma

(17). The MSI score was decreased significantly (58%,  $p=0.001$ ) by the end of 12 weeks compared to baseline.

We obtained QoL scores based on MELASQOL questionnaire, developed and validated by Balkrishnan in 2003. MELASQOL scale helps the physicians to understand the patient response toward treatment in both the psychological and the emotional manner. This is the most acceptable instrument to be applied for all the ethnic populations and has a high internal consistency, validity and a good discriminatory power, and is also suggested to be used for other dermatoses (18). This scale has been used in other studies (12, 19, 28). Using MELASQOL questionnaire, at the start of treatment, 86% of patients "bothered" for their skin appearance, had frustration and embarrassment regarding their skin condition; however, by Week 12, only 51% patients were "bothered" (a significant reduction from baseline). At the start of the treatment, the patients were asked few behavioral questions for their interaction with other people and emotional well being, it was found that 82% patients were not interactive with other people and 84% felt depressed and had feeling of unattractiveness due to their skin discoloration. At the end of the treatment, the number of such patients decreased to 49% and 51%, respectively. Further, at Week 12, 98% of patients in our study were ranked in the "not bothered" category for overall treatment effectiveness and QoL improvement. At the end of treatment, there were no cases showing symptoms of dryness, erythema or skin irritation.

Till date, there are limited studies conducted on sequential regimen treatments. Multiphase treatment protocols are followed in cosmetic procedures like chemical peeling and laser treatments, where patients need to undergo many painful periodic treatment sessions(3). Recently, a study by Goldman and his colleagues showed improved results with TC cream formulation when used sequentially with intense pulsed light (IPL) treatments for a period of 10 weeks, the results were effective, however the study reported a serious AE, i.e.,allergic reaction to intravenous pyelography dye (29).We are the first group to conduct a sequential phase study using unique combination therapies where patients received safe and painless treatment with promising results.

Our study suggests that this sequential regimen is a novel approach to treat melasma, where the treatment was well tolerated, with minor AEs, which were expected through the action of the medication. However the study has few limitations; it was performed in a single ethnic population with a limited number of patients and skin phototypes. The results need to be applied to different racial groups and larger population groups with representation from multiple skin phototypes. Further, longer duration studies

must be conducted to fill up the shortcomings of the present study considering the loss to follow-up cases and a short follow-up period.

### **Conclusion**

Sequential regimen of Depiwhite cream and Depiwhite advanced is a highly efficacious and safe treatment. It ensures long term compliance and convenience in treating melasma.

### **Acknowledgement**

We acknowledge the contribution of Mr. Prince Uppal, Wockhardt Ltd, for the support of study medication and Dr Sushil Chaudhary Skinovate Skin Laser center, Pune for assistance in study execution. We would also acknowledge the Knowledge Isotopes Pvt, Ltd (<http://www.knowledgeisotopes.com>) for medical writing.

### **Conflict of Interest**

The authors have no conflict of interest.

### **Funding**

This research did not receive any specific grant from funding agencies in the public, commercial, or not-for-profit sectors.

**Appendix 1: Progress Assessment Scale- MSI**

Melasma Severity Index (MSI) score			
Assessment Parameter	Baseline	Week 4	Week 12
Area of involvement	RF		
	LF		
	Nose		
Pigmentation	RF		
	LF		
	Nose		
<b>MSI Score</b>			

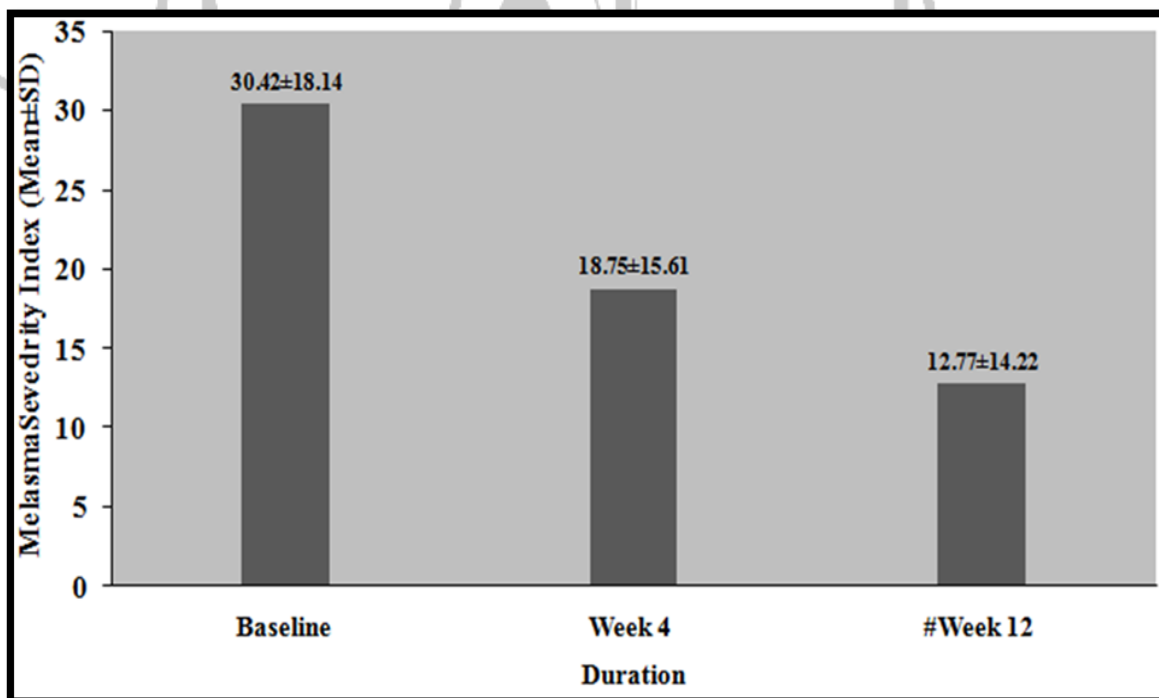
Severity Scoring For Pigmentation and Area of Involvement		
Score	Pigmentation	Area of involvement
0	No visible pigmentation	----
1	Barely visible pigmentation	≤ 10% area involved
2	Mild pigmentation	11-30%
3	Moderate pigmentation	31-60%
4	Severe pigmentation	>60%

MSI is calculated by multiplying the area of involvement with the square of pigmentation as given in formula:

$$MSI = 0.4 (a \times p^2) l + 0.4 (a \times p^2) r + 0.2 (a \times p^2) n$$

Where “a” stands for “area of involvement,” “p” for “severity of pigmentation,” “l” for left face, “r” for right face, and “n” for nose

**Figure 1: Changes in Melasma Severity Index (MSI) Scores**

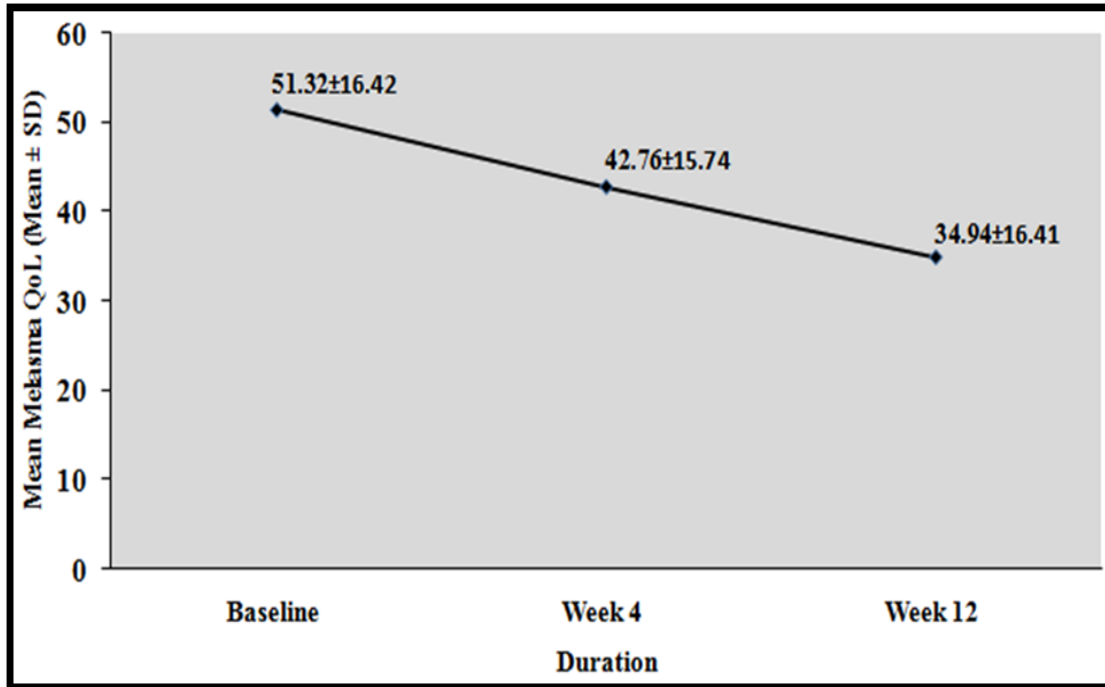


Mean diff (Baseline Week 4): \*-11.67 ± 9.35, Mean diff (Baseline Week 12): \*-17.65± 13.00

\* Significant p value= 0.001

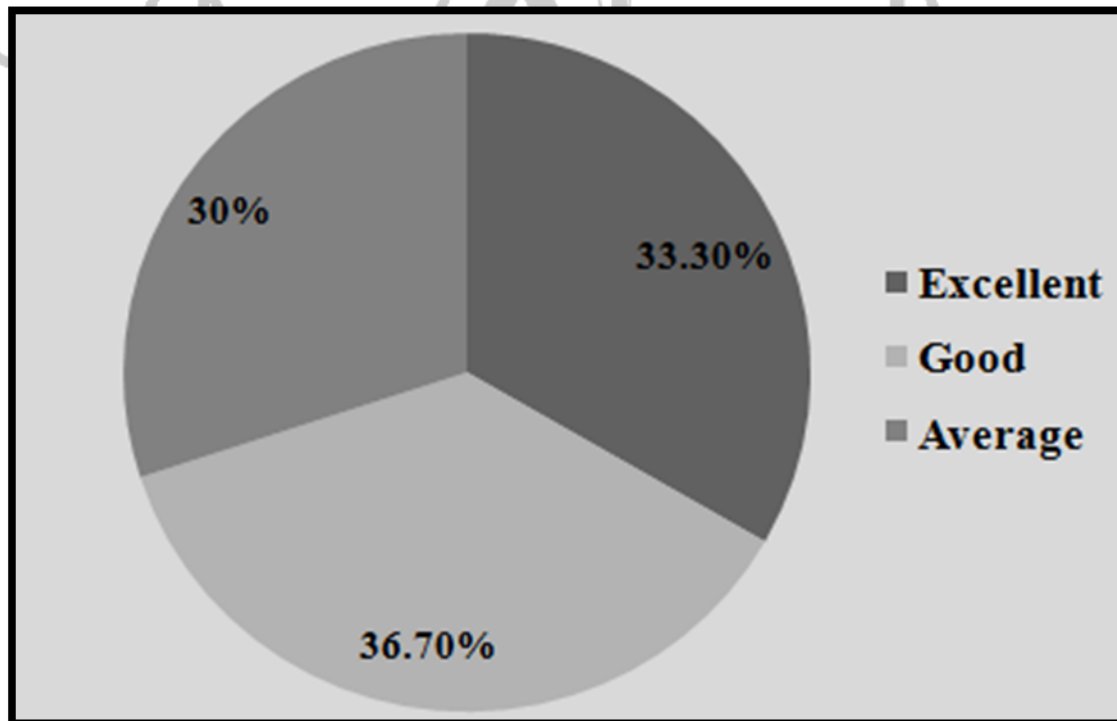


**Figure 2: Change in Mean Melasma Quality of Life (QoL) Scores**



Mean diff (Baseline Week 4):  $-08.56 \pm 6.36$ , Mean diff (Baseline Week 12):  $-16.38 \pm 12.29$   
 \* Significant p value= 0.001

**Figure 3: Profile of Global Investigator's Rating among Study cases**



*Investigator's Rating Scales: 1=Excellent; 2= Good; 3=Average*

**Table 1: Safety Outcomes: Changes in Mean Total AE and Mean Global AE scores**

Duration (Weeks)	Number of Patients	Mean Dryness Score (a) (Mean ± SD)	Mean Erythema Score (b) (Mean ± SD)	Mean Irritation Score (c) (Mean ± SD)	Mean Global AE score (a+b+c) (Mean ± SD)
Week 4	50	0.84± 0.68	0.10 ± 0.30	1.02± 0.87	1.96 ± 1.53
Week 12	50	0.00 ± 0.00	0.00 ± 0.00	0.00 ± 0.00	0.00 ± 0.00

**REFERENCES**

**Kang HY, Ortonne JP.** What should be considered in treatment of melasma. *Ann Dermatol.* 2010;22(4):373-8.

**Desai SR.** Hyperpigmentation therapy: a review. *J Clin Aesthet Dermatol.* 2014;7(8):13-7.

**Shankar K, Godse K, Aurangabadkar S, Lahiri K, Mysore V, Ganjoo A, et al.** Evidence-based treatment for melasma: expert opinion and a review. *Dermatology and therapy.* 2014;4(2):165-86.

**Chatterjee M, Vasudevan B.** Recent advances in melasma. *Pigment International.* 2014;1(2):70.

**Sarkar R, Bansal S, Garg VK.** Chemical peels for melasma in dark-skinned patients. *Journal of cutaneous and aesthetic surgery.* 2012;5(4):247-53.

**Ogbechie-Godec OA, Elbuluk N.** Melasma: an Up-to-Date Comprehensive Review. *Dermatology and Therapy.* 2017:1-14.

**Lajevardi V, Ghayoumi A, Abedini R, Hosseini H, Goodarzi A, Akbari Z, et al.** Comparison of the therapeutic efficacy and safety of combined oral tranexamic acid and topical hydroquinone 4% treatment vs. topical hydroquinone 4% alone in melasma: a parallel-group, assessor- and analyst-blinded, randomized controlled trial with a short-term follow-up. *Journal of cosmetic dermatology.* 2016

**Kauvar AN,** editor The evolution of melasma therapy: targeting melanosomes using low-fluence Q-switched neodymium-doped yttrium aluminium garnet lasers. *Seminars in cutaneous medicine and surgery;* 2012: Frontline Medical Communications.

**Kligman AM, Willis I.** A new formula for depigmenting human skin. *Archives of dermatology.* 1975;111(1):40-8.

**Majid I.** Mometasone-based triple combination therapy in melasma: Is it really safe? *Indian journal of dermatology.* 2010;55(4):359.

**Lahiri K, Coondoo A.** Topical steroid damaged/dependent face (TSDf): An entity of cutaneous pharmacodependence. *Indian journal of dermatology.* 2016;61(3):265.

**Cestari TF, Hexsel D, Viegas ML, Azulay L, Hassun K, Almeida AR,** et al. Validation of a melasma quality of life questionnaire for Brazilian Portuguese language: the MelasQoL-BP study and improvement of QoL of melasma patients after triple combination therapy. *Br J Dermatol.* 2006;156 Suppl 1:13-20.

**Rendon M BM, Arellano I, Picardo M.** Treatment of melasma. *J Am Acad Dermatol.* 2006;54:272-81

**Jow T, Hantash BM.** Hydroquinone-induced depigmentation: case report and review of the literature. *Dermatitis.* 2014;25(1):e1-5.

**Lin J, Chan H.** Pigmentary disorders in Asian skin: treatment with laser and intense pulsed light sources. *Skin Therapy Lett.* 2006;11(8):8-11.

**Yun WJ, Lee SM, Han JS, Lee SH, Chang SY, Haw S,** et al. A prospective, split-face, randomized study of the efficacy and safety of a novel fractionated intense pulsed light treatment for melasma in Asians. *J Cosmet Laser Ther.* 2015;17(5):259-66.

**Majid I, Haq I, Imran S, Keen A, Aziz K, Arif T.** Proposing Melasma Severity Index: A New, More Practical, Office-based Scoring System for Assessing the Severity of Melasma. *Indian J Dermatol.* 2016;61(1):39-44.

**Balkrishnan R, McMichael A, Camacho F, Saltzberg F, Housman T, Grummer S,** et al.

Development and validation of a health-related quality of life instrument for women with melasma. *British Journal of Dermatology.* 2003;149(3):572-7.

**Lieu TJ, Pandya AG.** Melasma quality of life measures. *Dermatol Clin.* 2012;30(2):269-80, viii.

**Sheth VM, Pandya AG.** Melasma: a comprehensive update: part II. *Journal of the American Academy of Dermatology.* 2011;65(4):699-714.

**Abou-Taleb DA, Youssef E, Ibrahim AK, Moubasher A.** Reliability and validity of the Arabic version of the Melasma Quality of Life questionnaire:(MELASQoL-A) study. *Clin Dermatol.* 2014;2:121-7.

**Finlay AY, Khan G.** Dermatology Life Quality Index (DLQI)—a simple practical measure for routine clinical use. *Clinical and experimental dermatology.* 1994;19(3):210-6.

**Balkrishnan R, McMichael AJ, Hu JY, Camacho FT, Shew KR, Bouloc A,** et al. Correlates of health-related quality of life in women with severe facial blemishes. *Int J Dermatol.* 2006;45(2):111-5.

**Chan R, Park K, Lee M, Lee ES, Chang S, Leow Y,** et al. A randomized controlled trial of the efficacy and safety of a fixed triple combination (fluocinolone acetonide 0·01%, hydroquinone 4%, tretinoin 0·05%) compared with hydroquinone 4% cream in Asian patients with moderate to severe melasma. *British Journal of Dermatology.* 2008;159(3):697-703.

**Godse KV.** Triple combination of hydroquinone, tretinoin and mometasone furoate with glycolic acid peels in

melasma. Indian journal of dermatology. 2009;54(1):92.

Depiwhite Advanced Cream - Uses, Side-effects, Reviews, and Precautions - Wockhardt - Tablet Wise - India. (n.d.). Last accessed on August 29, 2017, from <http://www.tabletwise.com/depiwhite-advanced-cream>. 2017.

**Kulhalli P, Chevli T, Karnik R, Sheth M, Mulgaonkar N.** Comparative potency of formulations of mometasone furoate in terms of inhibition of 'PIRHR' in the forearm skin of normal human subjects measured with laser doppler velocimetry. Indian J Dermatol Venereol Leprol. 2005;71(3):170-4.

**Ikino JK, Nunes DH, Silva VP, Frode TS, Sens MM.** Melasma and assessment of the quality of life in Brazilian women. An Bras Dermatol. 2015;90(2):196-200.

**Goldman MP, Gold MH, Palm MD, Colon LE, Preston N, Johnson LA,** et al. Sequential treatment with triple combination cream and intense pulsed light is more efficacious than sequential treatment with an inactive (control) cream and intense pulsed light in patients with moderate to severe melasma. Dermatol Surg. 2011;37(2):224-33.

